



PATIENT

Chimulo Ramirez

SPECIES

Feline

BREED

DSH

SEX

Male Neutered

AGE

2 years

WEIGHT

9.9lbs

INTERPRETED BY

Maggie Machen
Lamy, DVM
DACVIM (Cardiology)

IMAGING PERFORMED BY

Pamela Harrigan,
RDCS

HOSPITAL NAME

East Boston Animal
Hospital

REFERRING VET

Dr. Chopra

INVOICE

27801

DATE

12/3/22

PRESENTING CLINICAL SIGNS

History: June 2022: Owner reports heavy breathing after minimal exercise, otherwise, no clinical signs. Nov 2022: Labored breathing after physical activity or stress, otherwise, doing fine. No murmur noted. *Sedated with Torb for study*.

ECHOCARDIOGRAM FINDINGS

2D, m-mode, color flow and Doppler imaging is available.

Left ventricle: The LV diameter is normal with adequate myocardial function. The LV wall thicknesses are normal. The papillary muscles are normal. The endocardium appears normal.

Left atrium: The left atrium is normal in dimension. No obvious spontaneous contrast or thrombi seen.

Mitral valve: The mitral valve is normal in structure and mobility. No obvious systolic anterior motion is seen. No MR.

Aortic valve/Aorta: The aortic valve is normal in morphology and mobility. Normal aortic outflow velocity; laminar flow. No aortic insufficiency.

Right ventricle: Normal right ventricular diameter and morphology indicating no overt evidence of pulmonary arterial hypertension.

Right atrium: The right atrium is normal in dimension.

Tricuspid valve: The tricuspid valve appears normal with trivial tricuspid regurgitation.

Pulmonic valve/Pulmonary artery: The pulmonic valve is normal in morphology and mobility. No pulmonic insufficiency. Normal RVOT velocity; laminar flow.

Pericardium/other: No pericardial or pleural effusion noted. No obvious cardiac masses.

Heart rhythm: ECG reveals a sinus rhythm with an average HR of 220bpm.

2-Dimensional Measurements

Ao diam (cm)	0.9
LA diam (cm)	1.2
LA:Ao (Swe)	1.3
IVS thickness (cm)	0.36
LVID diastole (cm)	1.7
PW thickness (cm)	0.37
LVID systole (cm)	0.8
FS (%)	55

Doppler Measurements

PV Vmax (m/s)	1.2
AoV Vmax (m/s)	1.5
MR Vmax (m/s)	NA
TR Vmax (m/s)	NA
TR PG (mmHg)	NA

INTERPRETATION OF THE FINDINGS

Overtly normal cardiac structure and function. The LV wall thickness is normal and there is no evidence of elevated left atrial pressure. No obvious congenital defects are seen at this time.

No structural cause for panting/exercise intolerance is identified and other possibilities should be considered.

It is important to note that phenotypic HCM can develop at any age and is often silent on exam. Routine screening is ideally recommended in any predisposed breed. Serial BNP monitoring can be used as a more economical alternative step; however, false positive results are possible.



PATIENT

Chimulo Ramirez

SPECIES

Feline

BREED

DSH

SEX

Male Neutered

AGE

2 years

WEIGHT

9.9lbs

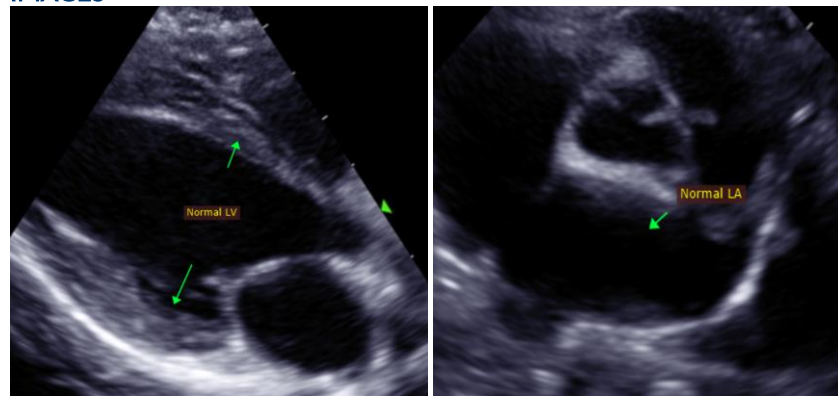
RECOMMENDATIONS

- Given these findings, no medications are indicated.
- No cardiac contraindication for general anesthesia.
- Monitor for any clinical evidence of cardiac compromise, including respiratory changes and/or signs of a blood clot event (paralysis, neurologic changes, etc.).

PLAN

- Recommend recheck echocardiogram periodically to screen for silent disease, sooner if worsening clinical signs, heart murmur or gallop are noted in the future.

IMAGES



INTERPRETED BY

Maggie Machen
 Lamy, DVM
 DACVIM (Cardiology)

The information and recommendations provided are based on the images presented by the referring veterinarian. No evaluation can be communicated regarding pathology that was not visible in the image/video clips provided.

Thank you for this referral. This report was generated using transcription software, and minor dictation errors may be present. If the clinical or image interpretation does not parallel your findings or if I can be of any further assistance, please contact me.

IMAGING PERFORMED BY

Pamela Harrigan,
 RDCS

Maggie Machen Lamy, DVM
Diplomate of the American College of Veterinary Internal Medicine (Cardiology)
 info@sonopath.com

HOSPITAL NAME

East Boston Animal
 Hospital

REFERRING VET

Dr. Chopra

INVOICE

27801

DATE

12/3/22